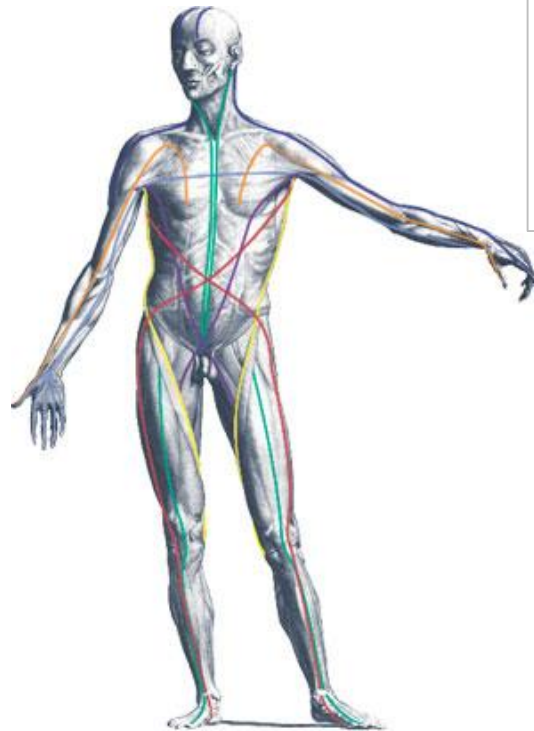


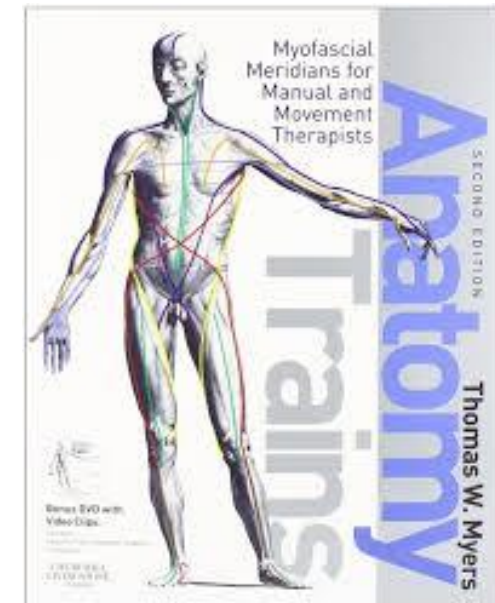
What are the Myofascial Lines?

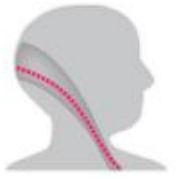Thomas Myers describes 12 Myofascial lines:

- Superficial Front Line
- Superficial Back Line
- Lateral Line
- Functional Lines
- Spiral Line
- Deep Front Line
- Arm Lines



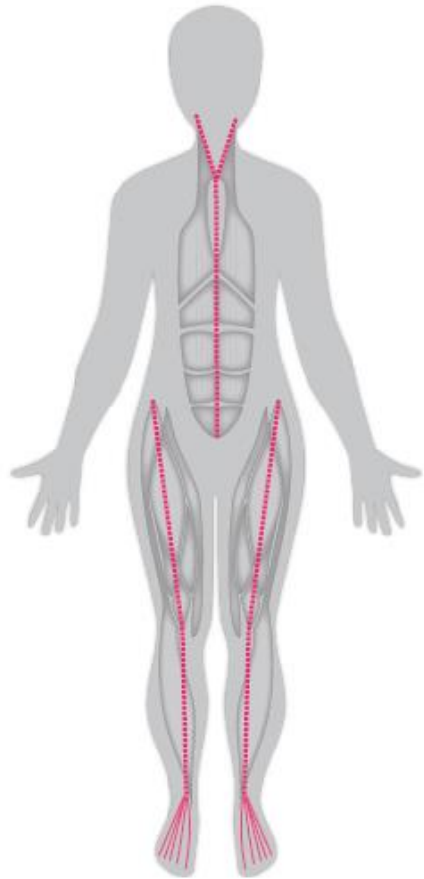
I would highly recommend that you purchase this book as it forms the foundation of this education and is a wonderful roadmap on which to base your work with bodies on





The Superficial Front Line

- Extensor Digitorum Longus and Brevis
- Tibialis Anterior
- Patellar Tendon
- Quadriceps (including the Rectus Femoris)
- Rectus Abdominis
- Sternalis
- Sternocleidomastoid

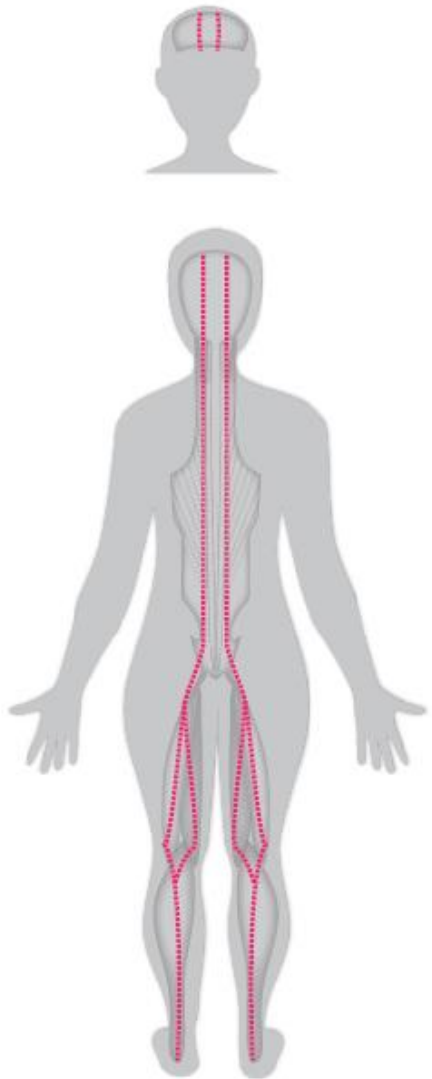


ANTERIOR

SUPERFICIAL FRONT LINE

The Superficial Back Line

- Flexor Digitorum Brevis
- Gastrocnemius
- Hamstrings
- Sacrotuberous Ligament
- Erector Spinae
- Scalp Fascia

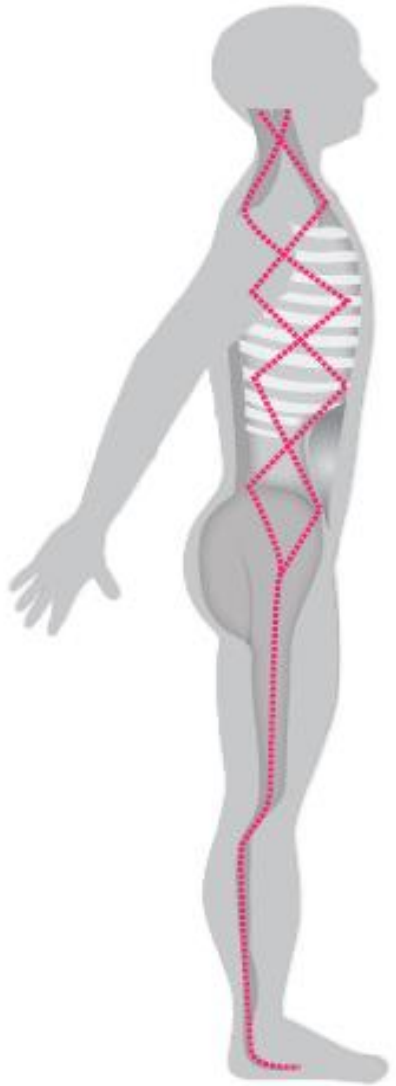


POSTERIOR

SUPERFICIAL BACK LINE

The Lateral Lines

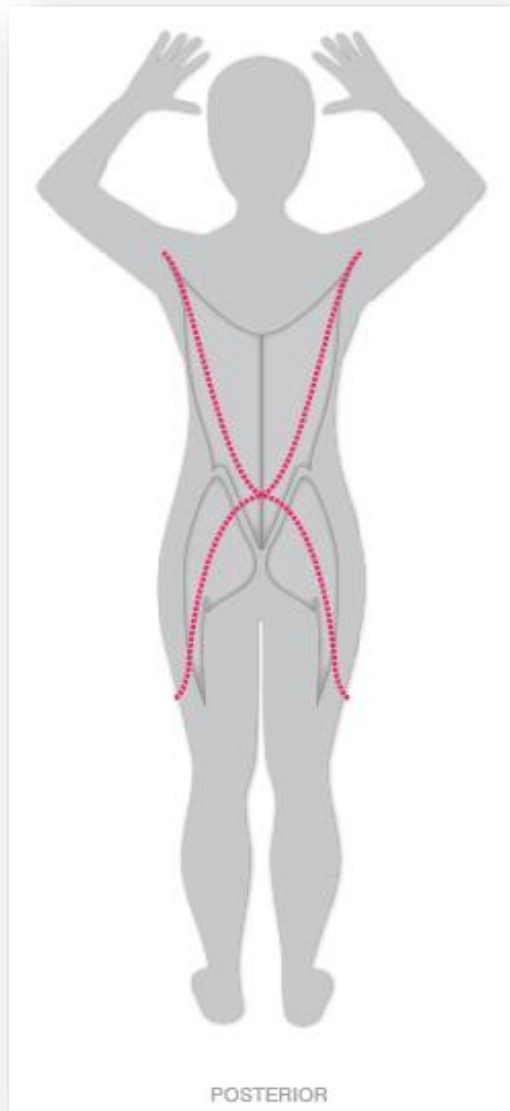
- Peroneus Longus and Brevis
- Anterior Ligament of the Fibular Head
- It-Band, TFL, Glute Max.
- Lateral Abdominal
- External and Internal intercostals
- Splenius Capitis and SCM



LATERAL LINE

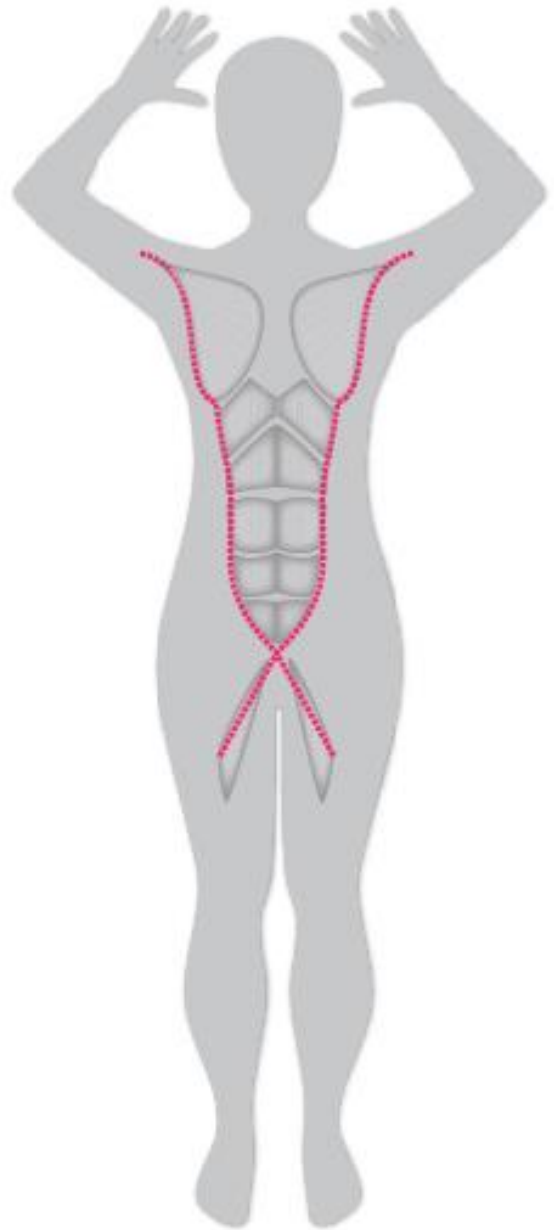
Back Functional Line

- Latissimus Dorsi
- Thoracolumbar Fascia
- Gluteus Maximus
- Vastus Lateralis
- Subpatellar Tendon



Front Functional Line

- Lower Pectoralis Major
- Lateral Rectus Abdominis and Abdominal Aponeurosis
- Adductor Longus



ANTERIOR

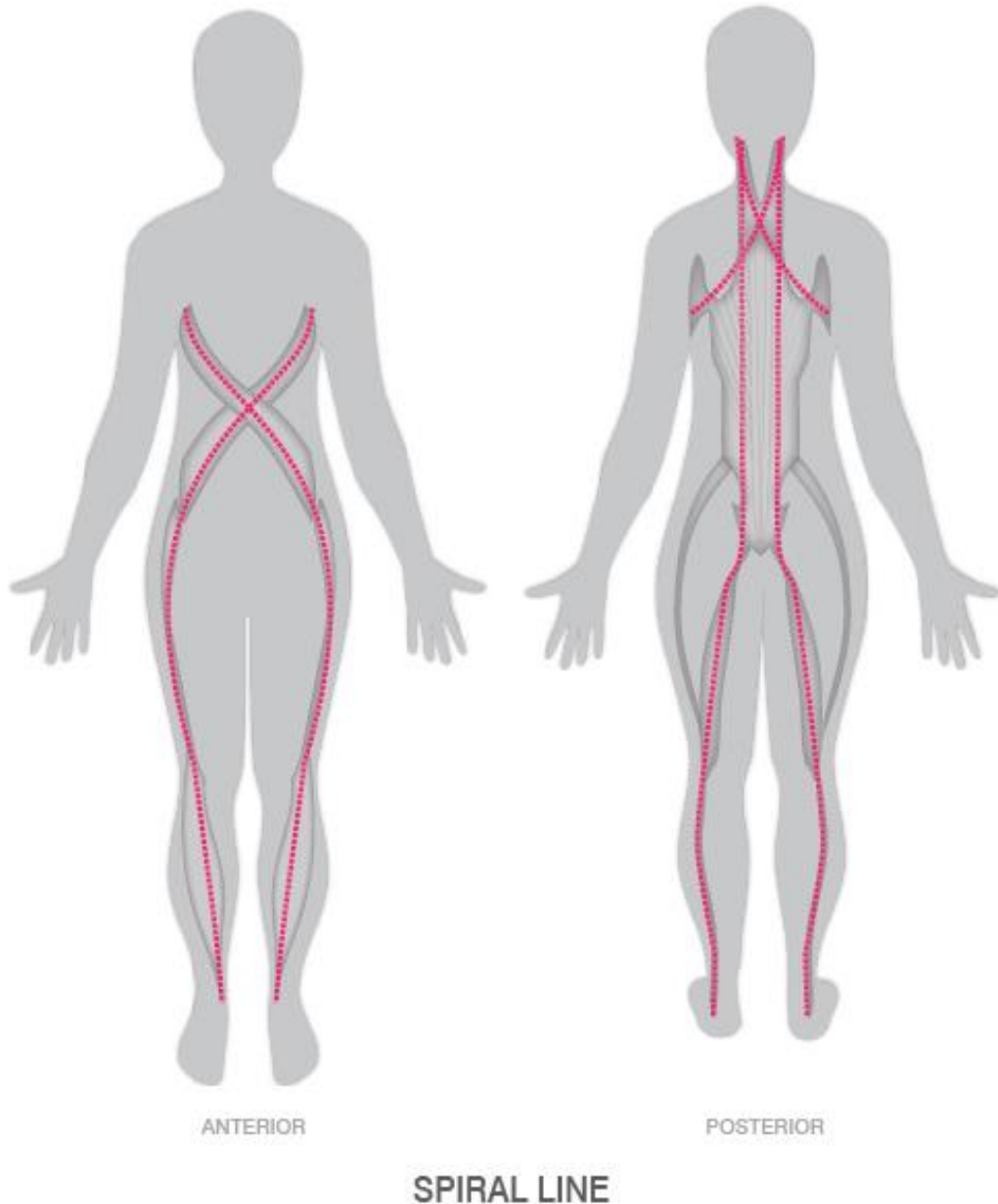
Spiral Line

Anterior View

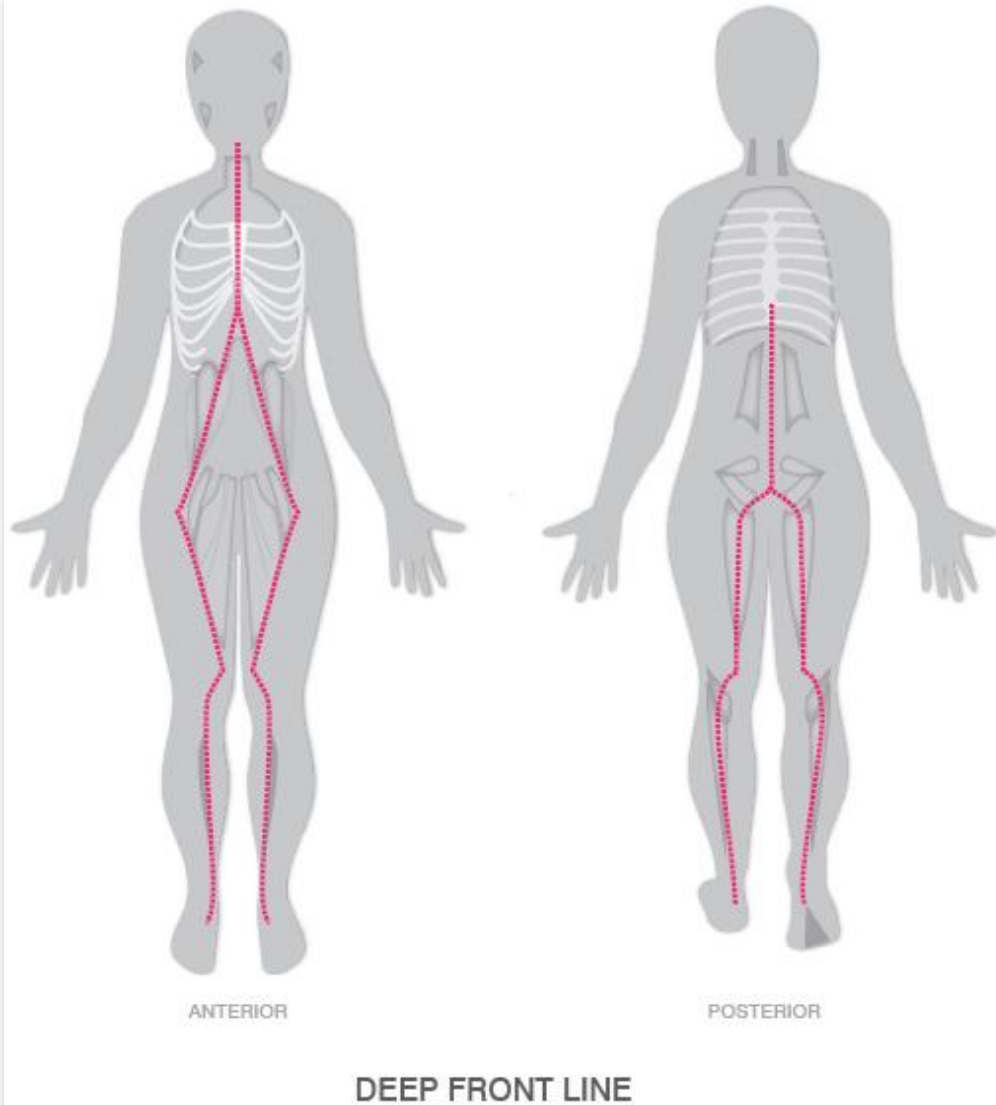
- Splenius capitus
- Rhomboids
- Serratus anterior
- External oblique
- Rectus sheath
- Internal oblique
- Tensor fascia latae
- ITB
- Tibialis anterior

Posterior View

- Peroneus longus
- Biceps femoris S/L head
- Sacrotuberous ligament
- Spinae erectors



Deep Front Line



Lowest Common

- Tibialis posterior
- Long toe flexors
- Posterior inter-muscular septum
- Popliteus fascia

Lower Posterior

- Posterior intermuscular septum
- Adductor magnus and minimus
- Pelvic floor fascia, levator ani, obturator internus fascia

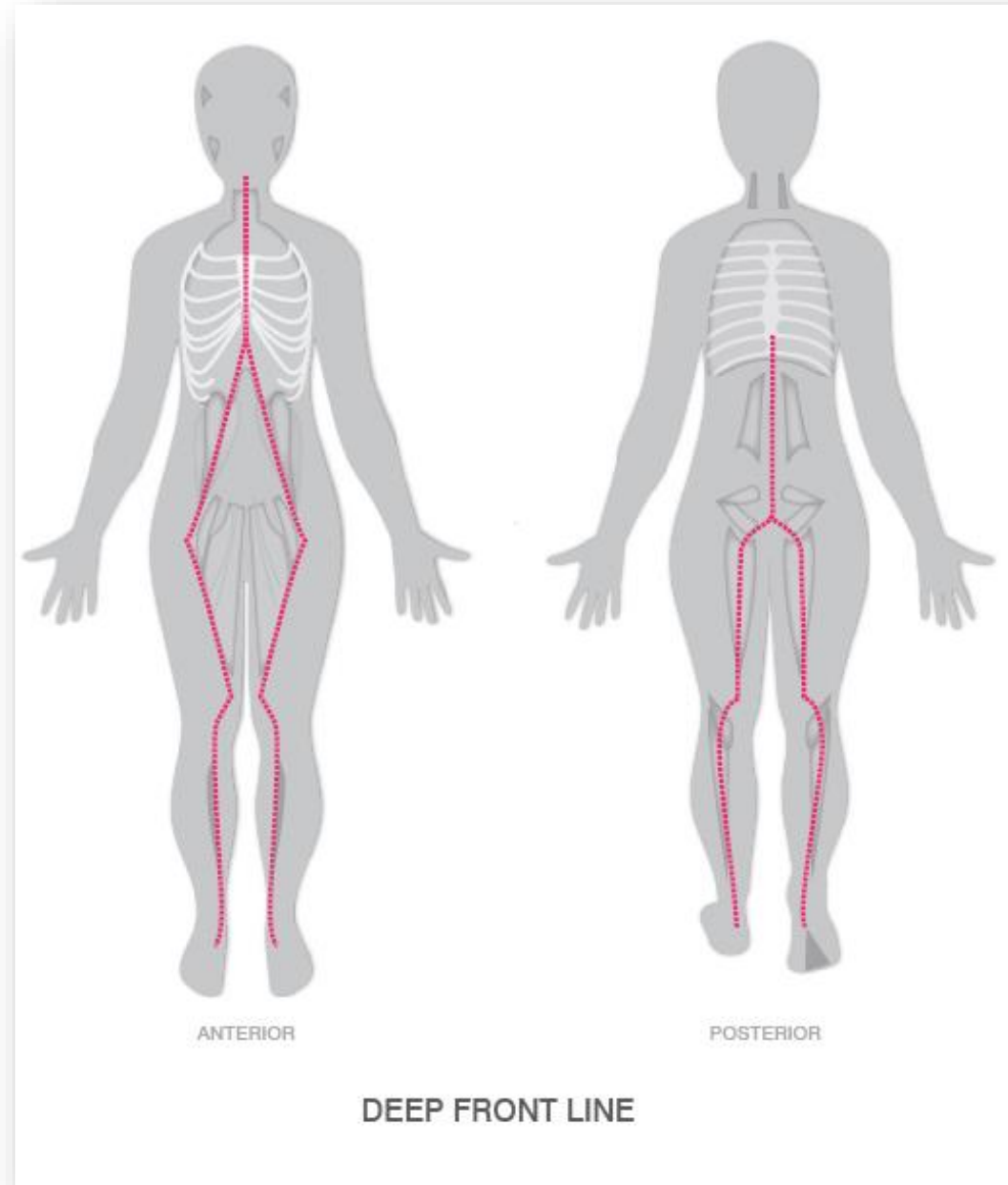
Deep Front Line

Lower Anterior

- Anterior inter-muscular septum
- Adductor longus, adductor brevis
- Pectineus
- Psoas, iliacus

Upper Posterior

- Anterior longitudinal ligament
- Longus colli
- Longus capitis



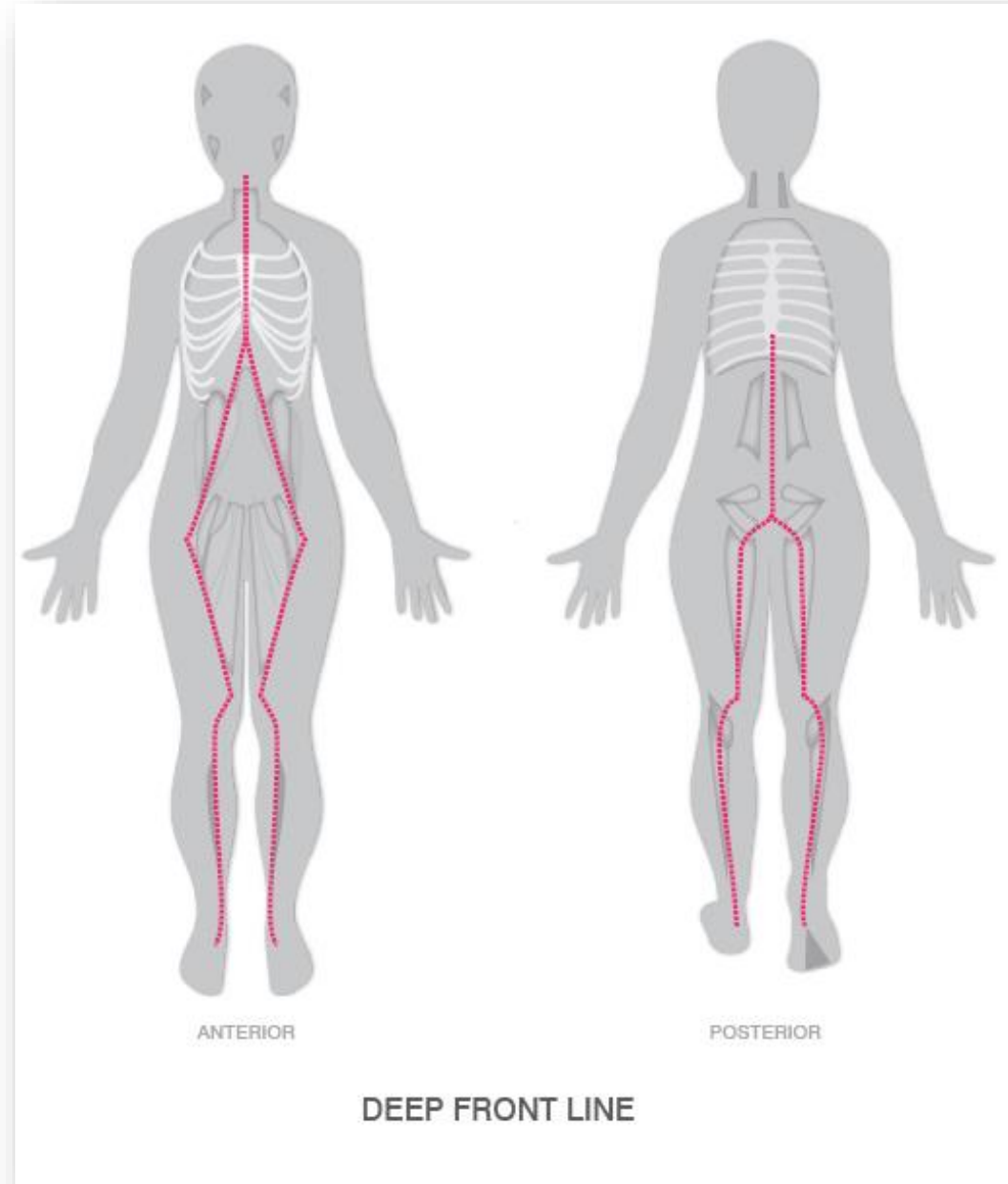
Deep Front Line

Upper Middle

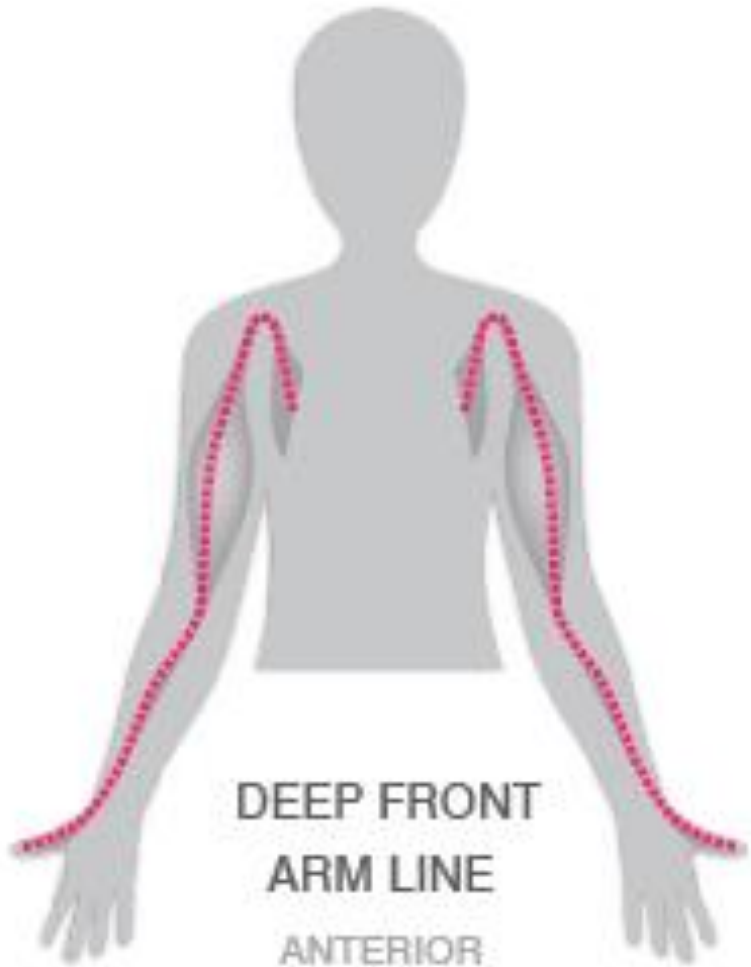
- Posterior diaphragm, central tendon
- Pericardium
- Scalene muscles

Upper Anterior

- Anterior diaphragm
- Infrahyoid muscles
- Suprahyoid muscles
- Jaw muscles

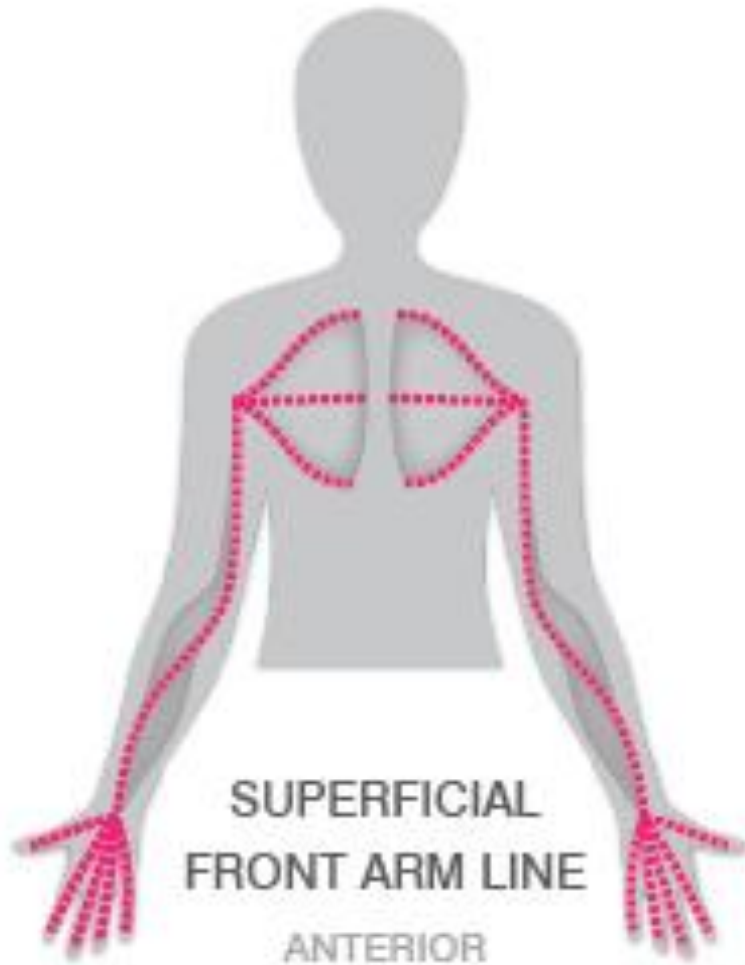


Deep Front Arm Line



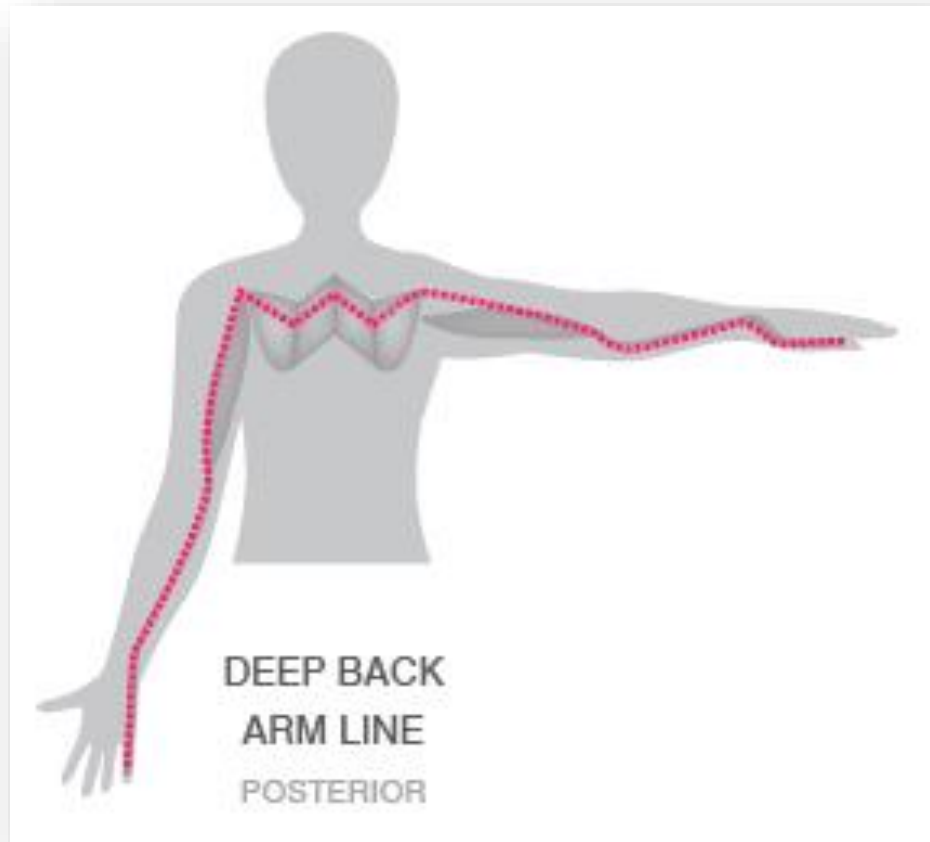
- Clavipectoral fascia
- Pectoralis minor
- Coracobrachialis
- Brachialis
- Biceps brachii
- Radial periosteum
- Thenar muscles

Superficial Front Arm Line



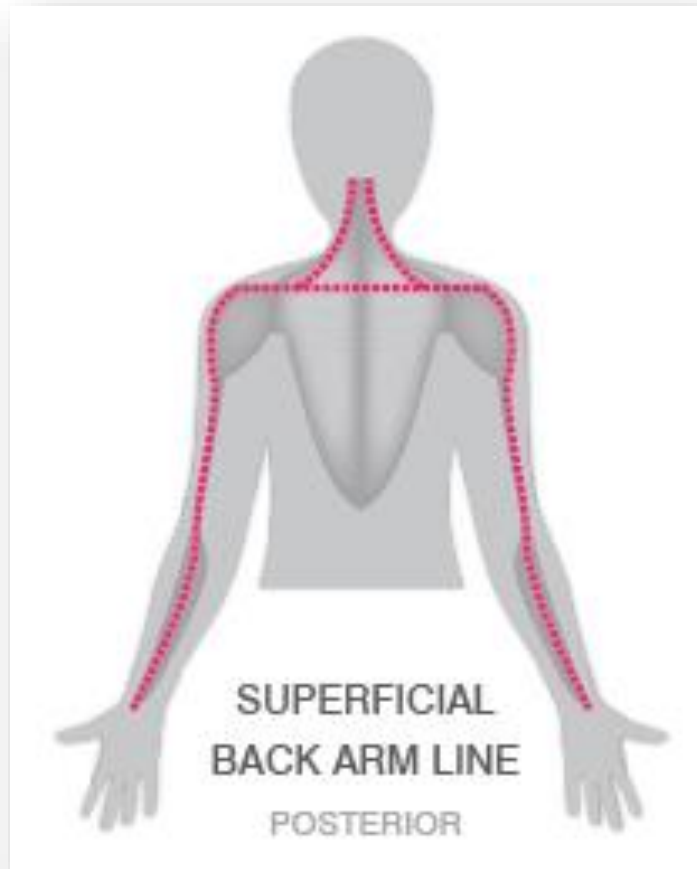
- Pectoralis major
- Latissimus dorsi
- Medial inter-muscular septum
- Flexor group
- Carpal tunnel

Deep Back Arm Line



- Rhomboids and levator scapulae
- Rotator cuff muscles
- Triceps Brachii
- Ulnar Periosteum
- Ulnar collateral ligaments
- Hypothenar muscles

Superficial Back Arm Line



- Trapezius
- Deltoid
- Lateral inter-muscular septum
- Extensor group